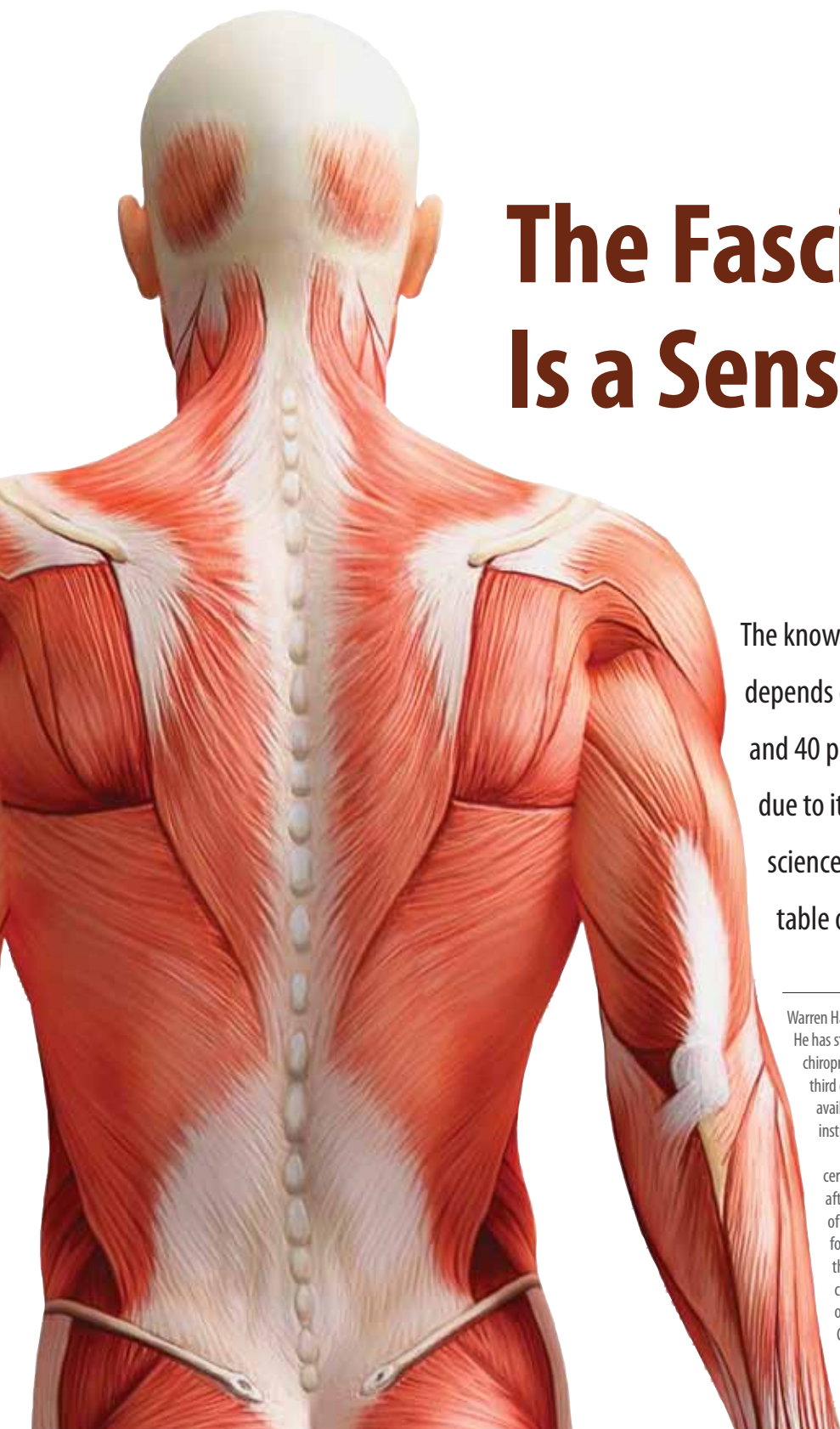

# The Fascial System Is a Sensory Organ

By Warren I. Hammer, DC

The knowledge that normal muscle function depends on the fascial system and between 30 and 40 percent of the force generated by muscle is due to its surrounding fascia can be compared in science to adding a new element to the periodic table of elements.

---

Warren Hammer, DC, MS, DABCO has been in practice in Norwalk, Conn., for 50 years. He has studied numerous soft-tissue methods and applies them to the practice of chiropractic. He has lectured nationally and internationally and recently completed his third edition of *Functional Soft-Tissue Examination and Treatment by Manual Methods*, available from Jones & Bartlett publishers. Dr. Hammer has been a consultant and instructor for Graston Technique® since 2001.

About two years ago, Dr. Hammer became certified in the use of Fascial Manipulation© (FM) after spending two weeks in Italy under the tutelage of Luigi Stecco, PT. FM has been taught in Europe for the past 15 years and is presently being taught throughout the world. As of 2013, he has become a certified instructor and is introducing this method of treatment with Antonio Stecco, MD, and Stefano Casadei, PT, into the United States.



Science has dismissed the value of a connective tissue structure that encompasses our whole body both internally and externally. Carla Stecco, MD, elaborated this dismissal in her upcoming text entitled, *Functional Atlas of the Human Fascial System* (Elsevier 2015): “In anatomy text books, only local areas of fasciae are described and they are characterized by only one of their minor functions: as an opaque covering.” In her preface, she adds that most anatomists view connective tissue as something to remove so that joints, muscles, organs and tendons may be studied carefully. In fact, it has now been established that the basic function of joints, muscles, organs and tendons requires a normal, functioning fascial system.

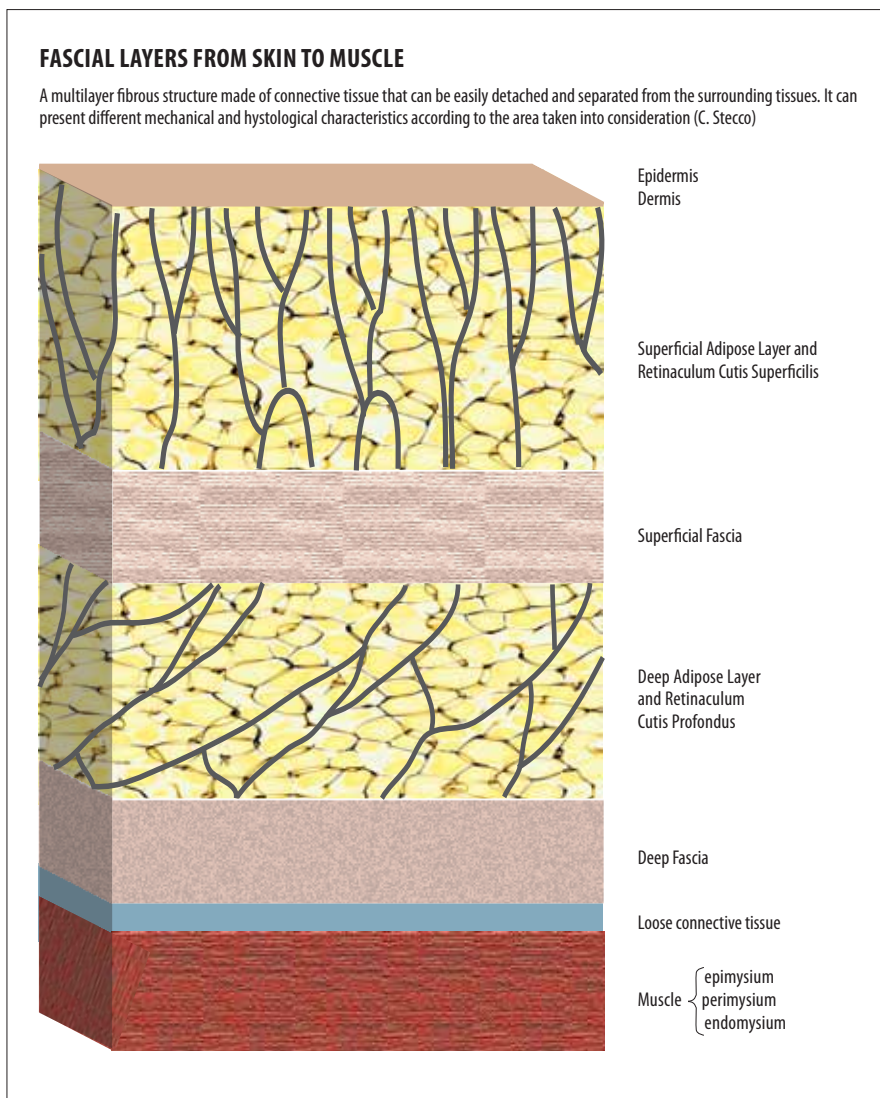
Research demonstrates that more than 30 percent of the force generated from the muscle is transmitted not along a tendon, but rather by the connective tissue within the muscle<sup>1,2,3,4</sup> and fascia contains mechanoreceptors and proprioceptors.<sup>5,6,7,8</sup> In other words, every time we use a muscle, we stretch fascia that is connected to spindle cells, Ruffini and Paccini corpuscles and Golgi organs. The normal stretching of fascia thus communicates the force of the muscle contraction and the status of the muscle regarding its tone, movement, rate of change in muscle length and position of the associated body part to the central nervous system (CNS).

An important question now arises: What if the fascia, where these receptors are located, is restricted due to increased viscosity or is chronically overstretched? As receptors are activated by pressure or stretch, is it possible that the receptors, which must be free to function, are inhibited? Could inhibition of receptor function provide altered feedback to the CNS? The fascia is therefore much more than an “opaque covering.” It should probably be designated as another organ of the body. Something else to consider: The acupuncture system is within the fascial system. Langevin<sup>9</sup> described the network of acupuncture points and meridians as a network formed by connective tissue (fascia). Practitioners must understand what causes fascia to become pathological and why it disrupts function. Ultimately, they need to know how to restore normality to the fascial system.

### Anatomy and Physiology

This article is a very short introduction to the subject of fascia, but certain anatomical and physiological information has to be understood. Muscles are covered by specific types of deep fascia (see Fig. 1) designated as either epimysial or aponeurotic fascia.<sup>10</sup> In the extremities, a thin layer of epimysial fascia called the epimysium envelops the surface of each muscle. It surrounds the entire surface of the muscle belly and separates it from adjoining muscles. It gives form to all of the extremity muscles. In the extremities, the epimysium is covered by aponeurotic fascia (AF). The fascia lata is aponeurotic fascia that covers the whole thigh and buttock like a stocking and slides over the epimysium of the muscles beneath it. AF is the

Figure 1.



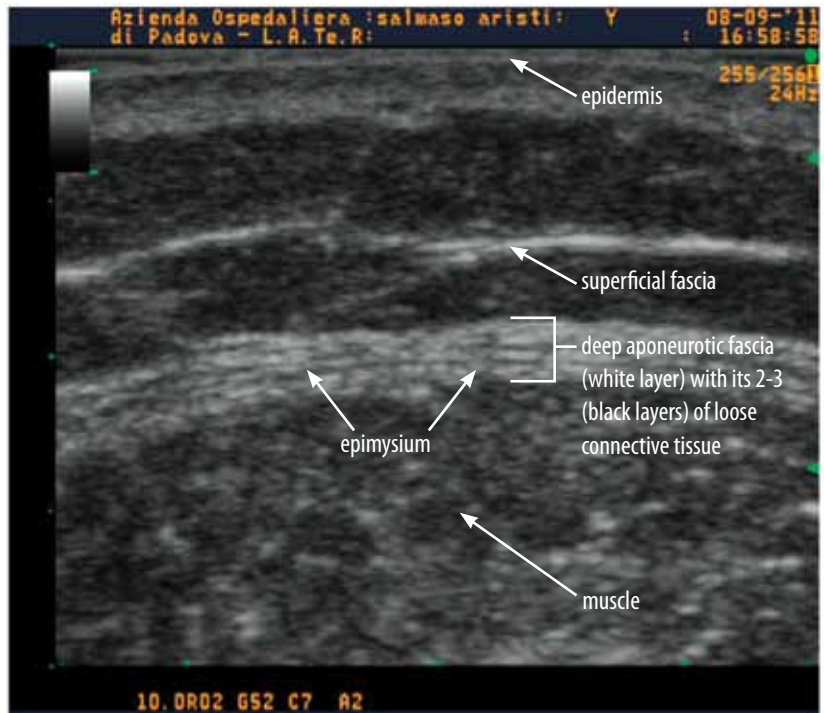
“well-defined fibrous sheaths that cover and keep in place a group of muscles or serve for the insertion of broad muscles.”<sup>11</sup> Some examples of AF are the thoracolumbar fascia, the fascia lata and the fascia that covers all of the extremity muscles. A principal function of the AF is to transmit the force (myofascial continuity) of the muscle groups it covers by way of myofascial expansions or insertions. These expansions insert into the periosteum, the paratenons, neurovascular sheaths and the fibrous capsules of joints.<sup>10</sup> During forward movement of the upper extremity for example, the clavicular fibers of the pectoralis major (epimysial fascia) upon contraction stretches the anterior brachial aponeurotic fascia. The biceps is contracting, thereby stretching the antebrachial (aponeurotic) fascia and by way of the lacertus fibrosus to the flexor carpi radialis and the thenar muscles. This sequence has been verified by dissection.<sup>12</sup>

Similarly, the quadriceps muscle inserts into the tibia by way of its tendon and continues on to a myofascial expansion that passes anterior to the patella to the anterior knee retinaculum. The Achilles tendon connects from the calcaneus to fascial attachments to the plantar fascia over the back of the heel and to the heel fat pad.<sup>10</sup> Every movement of the body will stretch particular patterns of intrafascial receptors, especially in the deep fascia. The firing of receptors embedded in the fascial network represents the perceptive continuity necessary for normal unimpeded movement and the transmission of information proximally and distally to adjoining muscles and to our CNS.

AF helps transmit the force of the muscles it covers and is innervated mostly in its superficial layer. Aponeurotic fascia in the extremities is separated from the epimysium by loose connective tissue, which allows normal glide between the two fascial layers. The AF is made up of two to three layers of parallel collagen fiber bundles, densely packed, separated by a thin layer of its own loose connective tissue. Each layer slides independently over its adjoining layer (see Fig. 2). The loose connective tissue with normal viscoelasticity allows normal tissue gliding. This gliding function becomes abnormal when the loose connective tissue viscosity increases.

Closely connected to the epimysium is an intramuscular fascial layer called the perimysium. The perimysium surrounds the muscle bundles (fascicles). Both the epimysium and perimysium are an organized framework that transmit the force produced in the locomotor system.<sup>13</sup> Both the epi and peri are thickened in tendinosis and with

**Figure 2: Ultrasound of normal Fascia lata.** Note the minimal thickness of the loose connective tissue layers. (With permission, Antonio Stecco, MD.)



immobilization.<sup>14</sup> From a sensory point of view, the chief proprioceptors for muscles are muscle spindles that are localized in the perimysium. Their capsules connect to the epimysium and fascial septae.<sup>6</sup> The chief sensory components of muscles, the spindle cells, reside in the fascia. Finally, there is the endomysium, which covers every muscle fiber and separates fibers from each other to allow individual fiber gliding.

## Pathology

The fact that spindle cells are in the fascia implies that if the fascia is altered – restricted or densified – the spindle cells may not function normally, depriving the CNS of necessary information about joint movement, muscle coordination and position. Spindle cells represent a common final pathway, since all proprioceptive input from fascia, ligaments, skin, etc., goes to the dorsal horn. The dorsal horn has collaterals that synapse on the gamma motor neurons causing reflex activation of spindle cells. Spindle cells are active even during sleep, and they must be stretched during muscle contraction or passive stretch to become activated. It is therefore probable that if the spindle cells are embedded in thickened, densified fascia, its ability to be stretched would be affected and normal spindle cell feedback to the CNS would be altered.

Siegfried Mense, MD, one of the world's lead-

ing experts on muscle pain and neurophysiology, when questioned about fascial adhesions having an adverse effect on spindle cells, answered: “Structural disorders of the fascia can surely distort the information sent by the spindles to the CNS and thus can interfere with a proper coordinated movement,” and “the primary spindle afferents (Ia fibers) are so sensitive that even slight distortions of the perimysium will change their discharge frequency.”<sup>15</sup> When our patients complain that the last thing they did was the cause of their pain (i.e., “must have gotten out of bed wrong”), they are already in an uncoordinated situation.

What is the actual mechanism of fascial disruption creating abnormal sensory afferentation? One of the chief causes of fascial restriction is related to a substance called hyaluronic acid (HA). HA is a high molecular weight glycosaminoglycan polymer of the extracellular matrix. Among its many functions, HA is a lubricant that allows normal gliding between joints and between connective tissue. The concept of gliding within the fascial system is crucial for normal fascial function. Normal gliding between the layers of fascia surrounding the muscle and within the muscle depends on the normal hydration provided principally by HA. HA is already proving successful when it is injected into osteo-

arthritic knees or frozen shoulders.<sup>16,17</sup> A major location of HA is in the loose connective tissue between the deep aponeurotic fascia and muscle (where aponeurotic fascia slides on the epimysium), the loose connective tissue between the two or three layers of the aponeurotic fascia and between the intramuscular fascia. Loose connective tissue appears as an irregular gelatinous mesh containing mainly HA, some fibroblasts, collagen and elastic fibers. “If the HA assumes a more packed conformation, or more generally, if the loose connective tissue inside the fascia alters its density, the behavior of the entire deep fascia and the underlying muscle would be compromised. This, we predict, may be the basis of the common phenomenon known as ‘myofascial pain.’”<sup>18</sup> There is evidence that if the loose connective tissue within the fascia has increased viscosity, the receptors will not be activated properly.<sup>19,20</sup> Densified HA also alters the distribution of the lines of force within the fascia. In this environment, pain and stiffness may be created with stretching, even within the physiological ranges.<sup>21</sup> When the HA chains become concentrated, their viscoelastic properties are altered, and this contributes to myofascial pain and the myofascial pain syndrome.<sup>18</sup>

There are corroborating studies that demonstrate the relationship between HA and myofascial pain. Under tissue stress, like tissue injury, hyaluronan becomes depolymerized and lower molecular mass polymers of hyaluronan fragments appear. These smaller HA fragments signal to the host that normal homeostasis has been profoundly disturbed.<sup>22</sup> Smaller HA fragments contribute to scar formation. With overuse and trauma, HA becomes fragmented and proinflammatory. “By increasing the concentration of HA, HA chains begin to entangle, conferring to the solution distinctive hydrodynamic properties: the viscoelasticity is dramatically increased.”<sup>23</sup> Other studies show that thoracolumbar fascia shear strain was approximately 20 percent lower in human subjects with chronic low-back pain. This reduction of shear plane motion may be due to abnormal trunk movement patterns and/or intrinsic connective tissue pathology.<sup>24</sup> Fascial thickening has been held responsible for chronic pain in both the neck<sup>25</sup> and lower back.<sup>26</sup> In the neck study, the thickness was found in the loose connective tissue, rather than the collagen fibers. In the lower-back study, the chronic low-back pain group had approximately 25 percent greater perimuscular thickness and echogenicity, compared

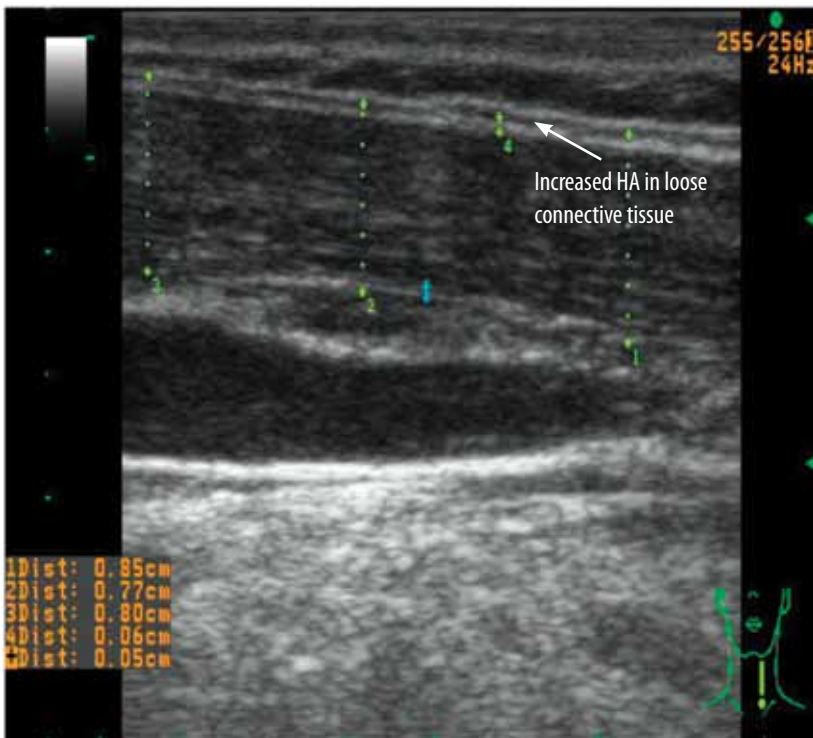


Figure 3. Increase in loose connective tissue space in patient with neck pain. (With permission, Antonio Stecco, MD.)

with the non-low-back pain group. In the chronic neck-pain study, the variation of thickness of the fascia correlated with the increase in quantity of the loose connective tissue, but not with dense connective tissue.<sup>21</sup> (See Fig. 3.) The value of 0.15 cm thickness of the sternocleidomastoid (SCM) fascia was considered as a cut-off value that allows the clinician to make a diagnosis of myofascial disease in a subject with chronic neck pain.

**R**estoring deep fascial glide requires a method of reaching the deep fascia, especially since this is the principal location of the spindle cells and the HA. In a study where the tissue was sensitized equally from the skin to the deep fascia in the erector spinae muscles, long-time sensitization to mechanical pressure and chemical stimulation remained in the deep fascia rather than the superficial areas.<sup>27</sup> Another study compared the methods of manual effects on restoring HA fluidity.<sup>28</sup> They compared perpendicular vibration and tangential oscillation with constant sliding motions. The perpendicular and tangential motions caused a greater HA lubrication than the sliding method. This demonstrates why it is important to treat an area long enough. The treatment area is less than 2 cm<sup>2</sup> and usually requires between 2 to 4 minutes<sup>29</sup> until palpation reveals a gliding sensation rather than a densification. As we treat the HA fragments, which are proinflammatory, they finally reach a size where they become anti-inflammatory.<sup>29,30</sup> This resultant reduction in inflammation takes about 48 hours. This may explain the possible side effects of continued pain after treatment. It is recommended that the same area should not be treated for at least four days or more. Vertical-type pressure using elbows, knuckles and Graston Technique® is necessary to effect this change.

## Conclusions

Much of the information in this article is derived from the research of Luigi Stecco, PT; Carla Stecco, MD, and Antonio Stecco, MD. They have created a modality called Fascial Manipulation® (FM), which is now being taught on almost every continent. Some basic principles of FM that readers might apply to their own methods of fascial treatment are:

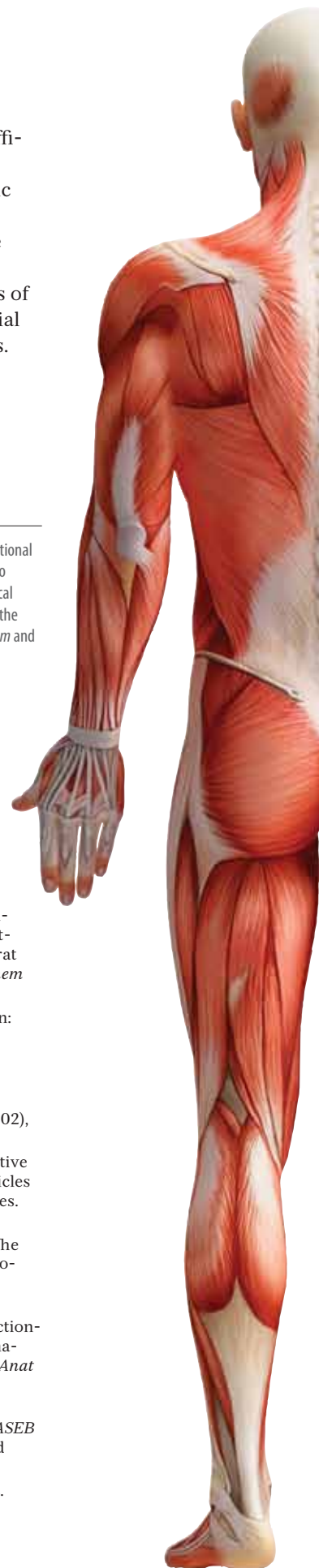
- ▶ The fascia is a sensory organ.
- ▶ Normal muscular function requires that its surrounding fascia be hydrated to allow normal tissue gliding.

- ▶ Improper tissue gliding is directly related to mechanoreceptive and proprioceptive insufficiency and muscle incoordination.
- ▶ Dysfunction follows along myofascial kinetic chains, especially those that relate to both the anatomical myofascial and acupuncture meridian fascial planes.
- ▶ A thorough case history that considers areas of previous trauma or surgery may reveal fascial densities responsible for present complaints.
- ▶ Functional testing and palpation of fascial planes are a primary diagnostic method.
- ▶ Treatment of affected points should be continued until normal density is palpated and negative functional testing improves. ■

Much of the research regarding these questions can be found in the U.S. National Library of Medicine, National Institutes of Health ([www.pubmed.com](http://www.pubmed.com)). Go to Stecco C or Stecco A, and you will find about 80 entries. Both of these medical researchers and others have investigated the works of Luigi Stecco, PT, and the fascial system. Go to [www.fasciaresearch.com](http://www.fasciaresearch.com), [www.fascialmanipulation.com](http://www.fascialmanipulation.com) and [www.fascialmanipulationworkshops.com](http://www.fascialmanipulationworkshops.com).

## References

- 1 Purslow PP. Muscle fascia and force transmission. *Journal of Bodywork & Movement Therapies* (2010)14: 411-417.
- 2 Huijing PA, Jaspers RT. Adaptation of muscle size and myofascial force transmission: a review and some new experimental results. *Scand J Med Sci Sports* (2005)15: 349-380.
- 3 Huijing PA, Baan GC. Myofascial force transmission causes interaction between adjacent muscles and connective tissue: effects of blunt dissection and compartmental fasciotomy on length force characteristics of rat extensor digitorum longus muscle. *Arch Physiol Biochem* (2001) 109:97-109.
- 4 Huijing PA. Epimuscular myofascial force transmission: A historical review and implications for new research. *J Biomech* (2009)42: 9-21.
- 5 Boyd-Clark LC, Briggs CA, Galea MP. Muscle spindle distribution, morphology, and density in longus colli and multiidus muscles of the cervical spine. *Spine* (2002), 27:694-70.
- 6 Maier A. Proportions of slow myosin heavy chain-positive fibers in muscle spindles and adjoining extrafusal fascicles and the positioning of spindles relative to these fascicles. *J Morphol.* (1999) 242:157-65.
- 7 Stecco C, Macchi V, Porzionato A, Stecco A et al. 2010. The ankle retinacula, morphological evidence of the proprioceptive role of the fascial system. *Cells Tissues Organs* (2010)192:200-10.
- 8 Strasmann T, van der Wal JC, Halata Z, Drukker J. Functional topography and ultrastructure of periarticular mechanoreceptors in the lateral elbow region of the rat. *Acta Anat (Basel)*. (1990)138(1):1-14. PubMed PMID: 2368595.
- 9 Langevin HM, Churchill DL, Wu J et al., Evidence of Connective Tissue Involvement in Acupuncture. *The FASEB Journal* express article 10.1096/fj.01-0925fje. Published online April 10, 2002.
- 10 Stecco C. *Functional Atlas of the Human Fascial System*. Elsevier (2015), in print.



- 11 *Stedman's Medical Dictionary*. 26th ed. Baltimore. Williams & Wilkins; 1995.
- 12 Stecco A, Macchi V, Stecco C, Porgionato A, Day JA et al. Anatomical study of myofascial continuity in the anterior region of the upper limb. *J Bodyw Mov Ther*. 2009 Jan;13(1):53-62.
- 13 Passerieux E, Rossignol R, Letellier T, Delage JP. Physical continuity of the perimysium from myofibers to tendons: involvement in lateral force transmission in skeletal muscle. *J Struct Biol*. (2007) Jul;159(1):19-28.
- 14 Järvinen TA, Józsa L, Kannus P et al. Organization and distribution of intramuscular connective tissue in normal and immobilized skeletal muscles. An immunohistochemical, polarization and scanning electron microscopic study. *J Muscle Res Cell Motil*. (2002);23(3):245-54.
- 15 Personal communication, Sigfried Mense MD, (2011).
- 16 Ishijima M, Nakamura T, Shimizu K et al. Intra-articular hyaluronic acid injection versus oral non-steroidal anti-inflammatory drug for the treatment of knee osteoarthritis: a multi-center, randomized, open-label, non-inferiority trial. *Arthritis Res Ther*. (2014)16(1):R18.
- 17 Ghosh P, Guidolin D. Potential mechanism of action of intra-articular hyaluronan therapy in osteoarthritis: are the effects molecular weight dependent? *Semin Arthritis Rheum*. (2002) Aug;32(1):10-37.
- 18 Stecco C, Stern R, Porzionato A et al. Hyaluronan within fascia in the etiology of myofascial pain. *Surg Radiol Anat* (2011), 33:891-896.
- 19 Swerup C, Rydqvist B. A mathematical model of the crustacean stretch receptor neuron. Biomechanics of the receptor muscle, mechanosensitive ion channels, and macrotransducer properties. *J Neurophysiol* 76, (1996):2211-2220.
- 20 Wilkinson RS, Fukami Y. Responses of isolated Golgi tendon organs of cat to sinusoidal stretch. *J Neurophysiol* 49, (1983):976-988.
- 21 Stecco A, Gesi M, Stecco C. Fascial components of the myofascial pain syndrome. *Curr Pain Headache Rep*, (2013) 17, 352:1-10.
- 22 Noble PW. Hyaluronan and its catabolic products in tissue injury and repair. *Matrix Biol*. (2002) Jan;21(1):25-9.
- 23 Matteini P et al., Structural behavior of highly concentrated hyaluronan. *Biomacromolecules*. (2009) 8;10(6):1516-22.
- 24 Langevin HM, Fox JR, Koptiuch C et al., Reduced thoracolumbar fascia shear strain in human chronic low back pain. *BMC Musculoskelet Disord*. (2011) Sep 19;12:203.
- 25 Stecco A, Meneghini M, Stern R, Stecco M, Imamura. Ultrasonography in myofascial neck pain: randomized clinical trial for diagnosis and follow-up. *Surg Radiol Anat* 2013.
- 26 Langevin HM, Stevens-Tuttle D, Fox JR, Badger GJ et al., Ultrasound evidence of altered lumbar connective tissue structure in human subjects with chronic low back pain. *BMC Musculoskelet Disord*. (2009) Dec 3;10:151
- 27 Deising S, Weinkauff B et al. NGF-evoked sensitization of muscle fascia nociceptors in humans. *J Pain* (2012), 153(8): 1673-9.
- 28 Roman M, Chaudhry H, Buklet B, Stecco A, Findly TW. Mathematical analysis of the flow of hyaluronic acid around fascia during manual therapy motions. *J Am Osteopath Asso*. (2013)(8):600-610.
- 29 Ercole B, Stecco A, Day JA, Stecco C. 2010 How much time is require to modify a fascial fibrosis? *J Bodyw Mov Ther*; 14:318-25.
- 30 Stern R, Asarib AA, Sugaharac KN. Hyaluronan fragments: An information-rich system. *European Journal of Cell Biology* 85 (2006) 699-715.

## Fascial Manipulation® WORKSHOPS

### 2014 Schedule of Courses

**Part 1A Minneapolis • April 11-13**  
**Part 1B Minneapolis • June 13-15**

**Part 2A Minneapolis • Aug. 1-3**  
**Part 2B Minneapolis • Aug. 22-24**

**Part 1A Stamford, CT • May 16-18**  
**Part 1B Norwalk, CT • June 20-22**

**Part 2A Stamford, CT • Oct. 10-12**  
**Part 2B Stamford, CT • Dec. 5-7**

Fascial Manipulation teaches current anatomy and physiology of the fascial system, its evaluation and treatment. Based on overwhelming peer review studies, you will learn:

- Treatment of the Myofascial Pain Syndrome
- Identification of essential causative points
- Treatment of the causative fascial anatomical/acupuncture sequences

CEU credits generally available.

FM courses are taught in four parts (1A and 1B; 2A and 2B). Taught by Stefano Casadei, PT, (Cesena, Italy) and Warren Hammer, DC, MS, DABCO. Each part is three days (Friday-Sunday), for a total of 12 days.

[www.fascialmanipulationworkshops.com](http://www.fascialmanipulationworkshops.com)

## Find-a-Doc

ACA is pleased to announce the "Find-a-Doc" online membership and patient referral database. ACA members can now list the various treatments and techniques their practice provides. Simply log on to your member profile at [www.acatoday.org](http://www.acatoday.org), and update your practice's information in just a few steps. This important FREE member benefit is a great way for potential patients and referring doctors to quickly find detailed information on ACA members practicing in their area. If you experience any problems using the new feature or if you have any suggestions, please contact us at [MemberInfo@acatoday.org](mailto:MemberInfo@acatoday.org).

